

Mechanisms of In-Stent Restenosis After Drug-Eluting Stent Implantation

Intravascular Ultrasound Analysis

Soo-Jin Kang, MD; Gary S. Mintz, MD; Duk-Woo Park, MD; Seung-Whan Lee, MD; Young-Hak Kim, MD; Cheol Whan Lee, MD; Ki-Hoon Han, MD; Jae-Joong Kim, MD; Seong-Wook Park, MD; Seung-Jung Park, MD

Background—We used intravascular ultrasound (IVUS) to (1) clarify the mechanisms of luminal loss after drug-eluting stent (DES) implantation and (2) classify morphological patterns of in-stent restenosis (ISR).

Methods and Results—On the basis of IVUS-identified luminal narrowing (in-stent minimum lumen area <4 mm²), IVUS-defined ISR was classified as focal (luminal narrowing ≤ 10 mm in length), multifocal (≥ 1 focal lesions), and diffuse (luminal narrowing >10 mm in length) with or without stent edge involvement. Significant intimal hyperplasia (IH) was defined as IH area $>50\%$ of stent. Overall, 76 lesions had IVUS-defined ISR; 32 (42%) had stent underexpansion (minimal stent area <5 mm²); and 71 (93%) had IH area $>50\%$ of stent. Total stent length negatively correlated with minimal stent area ($r = -0.613$, $P < 0.001$) as well as with stent area at the minimum lumen site ($r = -0.436$, $P < 0.001$) but not with minimum lumen area ($r = -0.084$, $P = 0.472$). Underexpansion was present at the minimum lumen site in 15 of 43 (35%) lesions with stent length >28 mm, even though there was significant IH in 34 (79%) lesions; conversely, in 32 of 33 (97%) lesions with stent length ≤ 28 mm, the minimum lumen site was not associated with stent underexpansion but significant IH. IVUS-defined focal ISR was most common (47%). Compared with focal ISR, normalized vessel, stent, lumen, and plaque volumes were smaller in diffuse and multifocal than focal ISR, with no difference in IH extent.

Conclusions—In most DES restenosis, IH was the dominant mechanism of ISR. Nevertheless, underexpansion associated with longer stent length remained an important preventable mechanism of ISR. (*Circ Cardiovasc Interv.* 2011;4:9-14.)

Key Words: in-stent restenosis ■ intimal hyperplasia ■ underexpansion ■ intravascular ultrasound

JOURNAL OF THE AMERICAN HEART ASSOCIATION

Drug-eluting stents (DES) reduce the rate of restenosis and the need for repeat revascularization compared with bare metal stents.¹⁻³ Previous studies suggested that rates of in-stent restenosis (ISR) and target lesion revascularization in lesions treated with bare metal stent significantly increased with stent length and the longitudinal extent of luminal narrowing and that the long-term outcome was heavily influenced by the angiographic patterns of the ISR process.⁴ Although quantitative coronary angiography has been used to assess late lumen loss, intravascular ultrasound (IVUS) provides more detailed and reliable information on the extent and distribution of intimal tissue, the presence of stent underexpansion, and vascular remodeling. The aims of the current study were to clarify the main mechanisms of ISR, especially at the minimum lumen site.

Clinical Perspective on p 14

Methods

Subjects

Angiographic restenosis was observed in 348 lesions treated with DES implantation between August 2004 and December 2007 from

the registry of Asan medical Center, Seoul, Korea. Among them, IVUS images at the time of the first ISR detection were available in 82 patients with 82 lesions (72 patients with repeat revascularization and 10 patients without repeated revascularization). From the same registry data, IVUS data of 312 lesions in 284 patients without angiographic restenosis served as the control group. These studies excluded patients with serious comorbid diseases or terminal illness, graft lesions, hemodynamic instability, ST-elevation myocardial infarction necessitating primary percutaneous intervention, and the inability of the IVUS-imaging catheter to cross lesions into the distal vessels because of severely narrowed lumen. All patients signed written informed consent.

Angiographic Analysis

Qualitative angiographic measurements were done by standard techniques with automated edge-detection algorithms (CASS-5, Pie-Medical, Maastricht, The Netherlands) in the angiographic analysis center of the CardioVascular Research Foundation, Seoul, Korea.⁵⁻⁸ Angiographic restenosis was defined as a diameter stenosis $>50\%$ at follow-up angiography and classified as suggested by Mehran et al.⁴

IVUS Imaging and Analysis

IVUS imaging was performed after intracoronary administration of 0.2 mg nitroglycerin using motorized transducer pullback (0.5 mm/s)

Received January 22, 2010; accepted November 15, 2010.

From the Department of Cardiology (S.-J.K., D.-W.P., S.-W.L., Y.-H.K., C.W.L., K.-H.H., J.-J.K., S.-W.P., S.-J.P.), University of Ulsan College of Medicine, Asan Medical Center, Seoul, Korea; and Cardiovascular Research Foundation (G.S.M.), New York, NY.

Correspondence to Seung-Jung Park, MD, Asan Medical Center, 388-1 Poongnap-dong, Songpa-gu, Seoul, South Korea, 138-736. E-mail sjpark@amc.seoul.kr

© 2011 American Heart Association, Inc.

Circ Cardiovasc Interv is available at <http://circinterventions.ahajournals.org>

DOI: 10.1161/CIRCINTERVENTIONS.110.940320

and a commercial scanner (Boston Scientific/SCIMED, Minneapolis, MN) consisting of a rotating 30- or 40-MHz transducer within a 3.2F imaging sheath. Quantitative volumetric IVUS analysis was performed as previously described.^{9,10} Using computerized planimetry (Echo-Plaque 3.0, Indec Systems, MountainView, CA), stent and reference segments were assessed every 1 mm. In-stent measurements were also obtained every 1 mm and included external elastic membrane (EEM), stent, lumen (intrastent lumen bounded by the borders of the stent and IH), persistent plaque+media (P+M=EEM minus stent), and intimal hyperplasia (IH=stent minus intrastent lumen) areas and volumes. Percent IH (%IH) was defined as IH area divided by stent area. All volumes were calculated using the Simpson rule and then normalized for analysis length (normalized volume). Stent underexpansion was defined as minimal stent area (MSA) <5 mm².¹¹ Significant IH was defined as %IH area >50%. Significant luminal narrowing was defined as IVUS-measured lumen area <4 mm².^{12,13}

In the present study, identification of ISR was based on IVUS-measured significant luminal narrowing; and ISR lesions were classified as follows.

1. Focal ISR was defined as lumen area <4 mm² and ≤10 mm in length confined to the body of stent (focal body type), or extending to the margins of stent (lumen area at the proximal or distal edge <4.0 mm², focal marginal type).
2. Multifocal ISR was defined as either multiple focal ISR lesions confined to the body of the stent (multifocal body type) without involvement of the stent margins or multiple focal ISR lesions that included marginal involvement (multifocal marginal type).
3. Diffuse ISR was defined as lumen area <4 mm² and >10 mm in length confined to the body of stent (diffuse body type) or extending to the margins of the stent (diffuse marginal type).

The mechanism of ISR was assessed at the minimum lumen site. Dominant stent underexpansion was defined as stent area <5 mm² and IH <50% at the minimum lumen site. Dominant intimal hyperplasia was defined as stent area >5 mm² and IH >50% at the minimum lumen site. Mixed underexpansion and intimal hyperplasia was defined as stent area <5 mm² and IH >50%.

Statistical Analysis

All statistical analyses were conducted using SPSS software (SPSS Inc, Chicago, IL). Categorical data were presented as counts and percentages and compared with χ^2 statistics or Fisher exact test. Continuous variables were compared by use of the unpaired or paired *t* test or nonparametric Mann-Whitney test. All IVUS parameters were compared among the 3 groups (focal, multifocal, and diffuse) using ANOVA with post hoc analyses using Bonferroni corrections for multiple comparisons of continuous variables. Receiver-operating curves were analyzed to assess the best cutoff values of total stent length that best separated an MSA <5 mm² from an MSA ≥5 mm² with a maximal accuracy, using MedCalc (MedCalc Software, Mariakerke, Belgium). The optimal cutoff was calculated by using Youden index. Pearson correlation coefficient was used to assess the association between parameters. Stepwise multiple regression analysis included the clinical and procedural variables such as age, sex, diabetes, hypercholesterolemia, and total stent length. All predictor variables were subsequently combined in a single regression model to assess their joint effects on the outcome variables by multivariable logistic generalized estimating equations model with robust standard errors that accounted for the clustering between lesions in same patient. The model for each outcome variable was reduced by using backward elimination until it contained only significant predictors. All probability values were 2-sided, and probability values less than 0.05 were considered to indicate statistical significance.

Results

Angiographic ISR Versus Non-ISR Lesions

Baseline clinical and procedural characteristics in 82 lesions with angiographic restenosis (37 sirolimus-eluting stents

Table 1. Baseline Clinical and Procedural Characteristics of 82 Lesions (82 Patients) With Angiographic Restenosis and 312 Lesions (284 Patients) Without Angiographic Restenosis

Variable	Angiographic Restenosis	No Angiographic Restenosis	P Value
Baseline clinical characteristics			
No. of patients	82	284	
Age, y	59.9±9.6	58.6±9.2	0.255
Male, n (%)	56 (68%)	227 (79%)	0.252
Smoking, n (%)	31 (38%)	94 (33%)	0.118
Hypertension, n (%)	47 (58%)	157 (55%)	0.133
Hypercholesterolemia, n (%)	56 (69%)	126 (44%)	<0.001
Diabetes mellitus, n (%)	30 (37%)	66 (23%)	0.003
Acute coronary syndrome, n (%)	35 (43%)	169 (59%)	0.070
Angiographic findings			
No. of lesions	82	312	
Chronic total occlusion, n (%)	5 (6%)	15 (5%)	0.737*
TIMI 0, n (%)	9 (11%)	21 (7%)	0.315*
Lesion location, n (%)			0.189*
Left anterior descending	55 (68%)	155 (50%)	
Left circumflex	7 (9%)	60 (19%)	
Right coronary	16 (19%)	87 (28%)	
Left main	3 (4%)	10 (3%)	
Bifurcation lesion	5 (6%)	28 (9%)	0.405*
Procedural details			
DES type			0.634*
SES	37 (45%)	158 (51%)	
PES	30 (37%)	101 (32%)	
ZES	15 (18%)	53 (17%)	
No. of DES per lesion	1.4±0.5	1.2±0.5	0.002*
Total stent length, mm	33.7±14.8	28.6±13.1	0.006*
Follow-up duration, mo	13.0±10.4	13.5±8.7	0.614

TIMI indicates Thrombolysis In Myocardial Infarction grade; clinical presentation at the time of ISR detection.

*Logistic regression using generalized estimating equations.

[SES], 30 paclitaxel-eluting stents [PES] and 15 zotarolimus-eluting stents [ZES]) and 312 lesions without angiographic restenosis are summarized in Table 1. Multivariable analysis including the clinical and procedural variables identified total stent length (adjusted odds ratio, 1.03; *P*=0.001; 95% confidence interval, 1.01 to 1.05), diabetes (adjusted odds ratio, 2.08; *P*=0.012; 95% confidence interval, 1.17 to 3.68), and hypercholesterolemia (adjusted odds ratio, 3.66; *P*<0.001; 95% confidence interval, 2.08 to 6.42) as the independent determinants for the angiographic restenosis. IVUS data at follow-up are summarized in Table 2.

Of 82 angiographically restenotic lesions, 76 (93%) also fit the definition of IVUS ISR (minimum lumen area [MLA] <4 mm²) and 32 (39%) had stent underexpansion (MSA <5 mm²). Conversely, in the 312 lesions without angiographic restenosis, IVUS-measured MLA <4 mm² was found

Table 2. Comparison of Intravascular Ultrasound Data Between Lesions With and Without Angiographic Restenosis

	Angiographic Restenosis	No Angiographic Restenosis	P Value
n	82	312	
Follow-up duration	12.9±10.4	13.5±8.7	0.615
MSA, mm ²	5.7±1.8	6.4±1.9	0.003
MLA, mm ²	2.2±1.0	5.4±1.9	<0.001
IH area at the narrowest lumen, %	4.7±2.2	1.4±1.2	<0.001
%IH area at the narrowest lumen, %	65.9±16.1	19.8±14.7	<0.001
MLA <4 mm ² , n (%)	76 (93%)	83 (27%)	<0.001
%IH area >50%, n (%)	69 (84%)	14 (5%)	<0.001
MSA <5 mm ² , n (%)	32 (39%)	75 (24%)	0.008
Normalized stent volume, mm ²	7.5±1.7	8.1±2.0	0.027
Normalized lumen volume, mm ²	5.2±1.4	7.1±2.0	0.001
Normalized IH volume, mm ²	2.3±1.1	1.0±0.7	0.002
Normalized EEM volume, mm ²	14.6±3.4	16.1±4.0	0.004
Normalized P+M volume, mm ²	7.0±2.4	8.0±3.1	0.021
%IH volume, %	31.0±12.5	12.1±8.5	<0.001

Logistic regression was performed using generalized estimating equations.

in 83 (27%) lesions; and underexpansion was detected in 75 (24%) lesions. Finally, 6 (7%) of angiographic restenotic lesions had a well-preserved MLA (≥ 4 mm²) on IVUS, although 4 of them had restenosis of reference segments.

Mechanisms Contributing to ISR

Among the 76 lesions with both angiographic and IVUS ISR, the minimum lumen site was located at mid portion in 59%, within 5 mm from the proximal stent edge in 22%, and within 5 mm from the distal stent edge in 19%. Overall, 32 (42%) had stent underexpansion (MSA <5 mm²) and 71 (93%) showed significant IH at some location within the stented segments and not only at the minimum lumen site. However, IVUS analysis at the minimum lumen site showed underexpansion in 16 (21%) lesions, 6 of which were not associated with significant IH (dominant underexpansion). Conversely, 67 (88%) lesions showed significant IH at the minimum lumen site suggesting that IH was the general mechanism of ISR irrespective of the presence of underexpansion (Figure 1).

Impact of Stent Length

In the overall cohort of 394 lesions with and without angiographic restenosis, there was a significant relationship between total stent length and MSA ($r = -0.365$, $P < 0.001$). Furthermore, in the 76 lesions with IVUS-defined ISR, total stent length negatively correlated with MSA ($r = -0.613$, $P < 0.001$, Figure 2) as well as vessel area ($r = -0.416$, $P < 0.001$), stent area ($r = -0.436$, $P < 0.001$), and %IH area ($r = -0.229$, $P = 0.047$) at the minimum lumen site but not with the MLA itself ($r = -0.084$, $P = 0.472$).

On receiver-operating curve analysis, total stent length of 28 mm was the cutoff value that best separated an MSA <5 mm² from an MSA ≥ 5 mm² with 70% sensitivity and

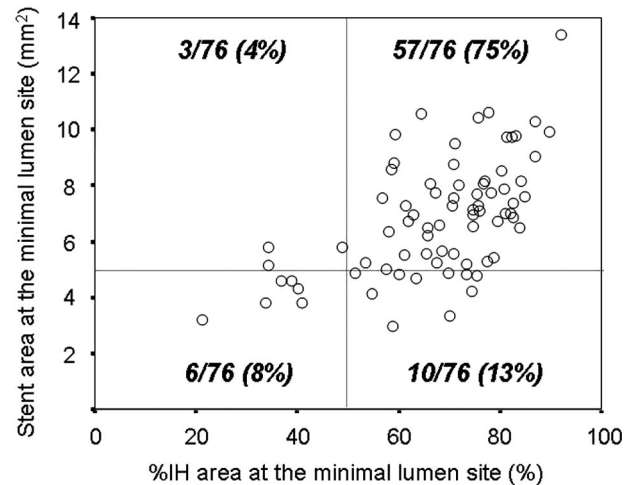


Figure 1. Mechanisms causing the luminal loss at the minimum lumen sites: Dominant stent underexpansion was defined as stent area <5 mm² and %IH <50%. Dominant intimal hyperplasia was defined as stent area >5 mm² and %IH area >50% of stent area. Mixed underexpansion and intimal hyperplasia was defined as stent area <5 mm² and %IH area >50% at the minimum lumen sites. The graph represents the ISR mechanisms in the overall cohort of 76 IVUS-defined ISR lesions.

61% specificity. Of 43 ISR lesions with total stent length >28 mm, 27 (63%) had underexpansion with MSA <5 mm² at some location, compared with only 5 (15%) of 33 ISR lesions with total stent length ≤ 28 mm ($P < 0.001$). At the minimum lumen site, underexpansion was present in 15 (35%) of 43 lesions with total stent length >28 mm, even though there was significant IH in 34 (79%) lesions. Moreover, underexpansion was the dominant mechanism of ISR in 6 (14%) of them (Figure 3). To the contrary, in 32 (97%) of 33 lesions with total stent length ≤ 28 mm, the MLA was not associated with stent underexpansion but only significant IH (dominant IH, Figure 4). In lesions with total stent length >28 mm, MSA was more frequently located at the distal edge compared with the lesions with total stent length ≤ 28 mm (49% versus 28%, $P = 0.044$). Total stent length had no relationship with stent area at proximal edge ($r = 0.072$,

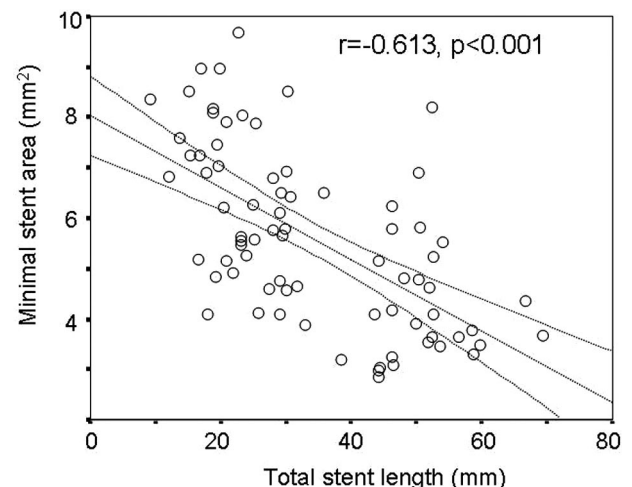


Figure 2. Relationship between total stent length and MSA in 76 lesions with IVUS-defined ISR ($r = -0.613$, $P < 0.001$).

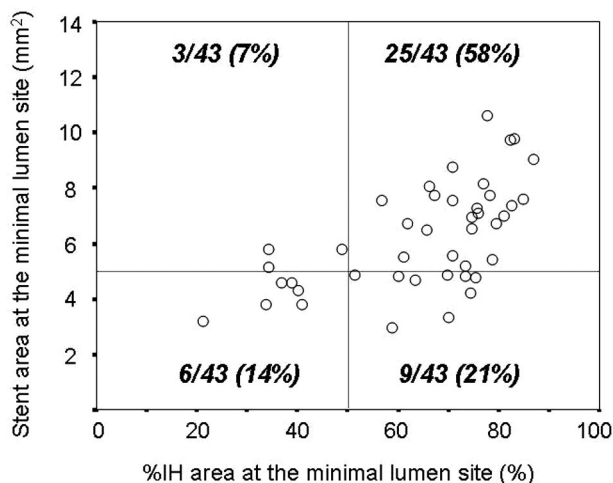


Figure 3. ISR mechanisms in 43 lesions with total stent length >28 mm.

$P=0.537$), whereas it negatively correlated with that at distal edge ($r=-0.594$, $P<0.001$).

In 312 non-ISR lesions on angiography, lesions with total stent length >28 mm also showed a higher frequency of underexpansion (MSA <5 mm²) versus lesions with total stent length ≤ 28 mm: 43 of 121 (36%) versus 32 of 191 (16%), $P<0.001$.

IVUS Patterns of ISR

Using “significant IVUS lumen narrowing” as the criterion for ISR, focal ISR was the most common pattern (47%). The mean lesion length of significant luminal narrowing was 12.7 ± 10.5 mm in 76 lesions. In 33 lesions with a total stent length ≤ 28 mm, the lesion length was 7.0 ± 4.6 mm; and the rates of focal, multifocal, and diffuse ISR were 70%, 15%, and 15%, respectively. In 43 lesions with total stent length >28 mm, the ISR length was 17.1 ± 11.6 mm ($P<0.001$ compared with lesions with a total stent length ≤ 28 mm); the rates of focal, multifocal, and diffuse ISR were 30%, 9%, and 61% ($P<0.001$ compared with lesions with a total stent length ≤ 28 mm). Comparison of IVUS parameters according

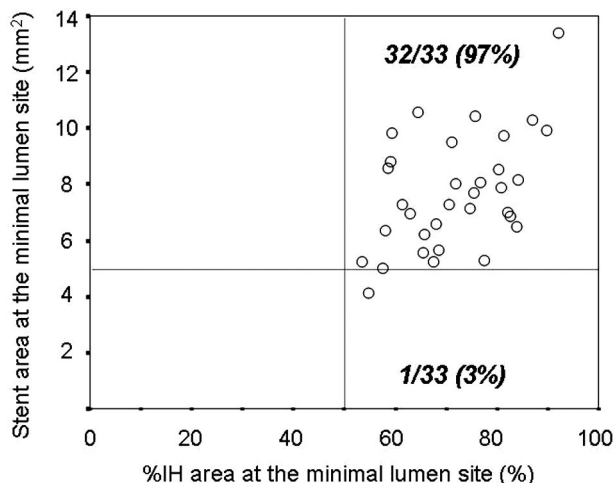


Figure 4. ISR mechanisms in 33 lesions with total stent length ≤ 28 mm.

to IVUS ISR patterns is shown in Table 3. Diffuse ISR group showed longer total stent length and higher rate of underexpansion (39%) at the minimum lumen site compared with focal (6%) or multifocal ISR (22%, $P=0.004$) but a similar rate of significant IH (90% versus 89% and 78%, $P=0.581$).

Comparing the 3 DES types, there were no differences in the frequencies of angiographic patterns of restenosis (overall $P=0.187$, Table 4) or IVUS patterns of restenosis (overall $P=0.545$, Table 5). With regard to the length of significant IH, >10 mm in length was observed in SES-treated lesions (9%), PES-treated lesions (32%), and ZES-treated lesions (33%) ($P=0.038$). PES-treated lesions showed a similar rate of underexpansion (14%) at the minimum lumen site compared with SES-treated lesions (27%) or ZES-treated lesions (20%, $P=0.461$) but a higher rate of significant IH (100% versus 79% and 87%, $P=0.037$).

At the minimum lumen site, although there was no significant difference in EEM, stent, lumen, and P+M area among 3 types of restenotic DES (data not shown), IH area (5.4 ± 2.3 mm² versus 4.1 ± 1.8 mm², $P=0.045$), and %IH area ($72.4\pm 11.4\%$ versus $62.5\pm 15.7\%$, $P=0.026$) were greater in PES than SES, with no difference between ZES (5.3 ± 2.2 mm² or $70.4\pm 15.5\%$) and SES or PES groups.

Discussion

An IVUS MLA <4.0 mm² is generally accepted to indicate significant luminal narrowing, and that has been used in previous studies as an IVUS definition of ISR. Although underexpansion has been emphasized as the most important mechanism of ISR, most cases of our study had significant IH at the minimum lumen site. Because stents do not chronically recoil, this indicated that IH remained as a general mechanism of luminal loss at the minimum lumen site irrespective of the presence of stent underexpansion. Furthermore, only 16 of 76 ISR lesions had stent underexpansion at the minimum lumen site, with all but 1 in the setting of a total stent length >28 mm. Conversely, 24% of the lesions without angiographic restenosis showed underexpansion as well.

Because IH was not preventable, interventionists should focus on correction of stent underexpansion during the procedure. A well-expanded stent can provide more room for intimal hyperplasia than an underexpanded stent. IVUS guidance may be helpful to avoid underexpansion especially in long lesions, small vessels, and other stenoses with complex characteristics.

Our data suggest several reasons why total stent length has remained an important predictor for angiographic restenosis even in the DES era.^{14,15} In this current analysis, total stent length significantly correlated with MSA as well as with the stent area at the minimum lumen site; longer stents had smaller in-stent areas and not just at the distal edge in smaller or tapering vessels. We believe that there is a greater possibility for “occult” focal stent underexpansion somewhere within the increased length of longer stents, leading to more severe luminal narrowing irrespective of IH. This may explain the higher restenosis rate in longer stented lesions. The current data indicated that diffuse ISR was associated with smaller stent and vessel areas that was, in turn, associated with a greater frequency of stent underexpansion compared with focal ISR.

Table 3. Comparison of IVUS Data According to ISR Patterns Classified by IVUS

	Total	IVUS Focal†	IVUS Multifocal†	IVUS Diffuse†	P Value
N	76	36	9	31	
Patient age, y	60.2±9.5	63.0±9.1	57.8±9.8	57.7±9.1	0.055
Total stent length, mm	34.3±15.0	27.5±12.8	30.8±13.6	43.1±13.7	<0.001
Stent No.	1.4±0.5	1.3±0.5	1.2±0.4	1.7±0.6	0.002
At the minimum lumen site					
EEM area, mm ²	13.5±4.0	15.5±4.3	11.6±2.3*	11.8±2.9*	<0.001
Stent area, mm ²	6.8±2.1	7.8±1.9	6.3±1.8	5.9±1.8*	0.001
Lumen area, mm ²	2.0±0.7	2.4±0.8	1.9±0.6	1.7±0.5*	<0.001
P+M, mm ²	6.7±3.0	7.7±3.4	5.4±2.2	5.9±2.2*	0.012
IH area, mm ²	4.8±2.1	5.4±2.2	4.4±2.4	4.3±1.9	0.077
%IH area, %	67.7±14.8	67.0±15.1	65.1±19.5	69.3±13.3	0.700
Plaque burden, %	48.2±11.7	48.1±11.5	45.5±12.9	48.9±11.9	0.736
Normalized stent volume, mm ²	7.4±1.6	8.4±1.4	6.8±1.5*	6.3±1.0*	<0.001
Normalized lumen volume, mm ²	5.0±1.2	5.9±0.9	4.5±0.5*	4.0±0.9*	<0.001
Normalized IH volume, mm ²	2.4±1.1	2.5±1.0	2.3±1.3	2.4±1.2	0.798
%IH volume, %	32.2±12.1	29.1±8.5	31.4±12.9	36.1±14.4	0.054
Normalized EEM volume, mm ²	14.3±3.4	16.3±3.4	12.4±1.7*	12.8±2.4*	<0.001
Normalized P+M volume, mm ²	7.0±2.4	7.9±2.6	5.6±1.4*	6.4±2.0*	0.006

*P<0.05 versus focal type; †including both body and marginal types. Nonparametric Mann-Whitney test.

Our study showed a high frequency of IVUS-defined focal ISR (47%) in DES restenosis. Additionally, >10 mm of significant IH was less common in SES than PES or ZES. These findings were comparable to previous angiographic data showing that the most common DES restenosis pattern is focal, especially in SES.^{16–19} Furthermore, the magnitude of IH was much greater in PES than in other DES (although the rate of underexpansion was similar), similar to another previous reports.²⁰ Considering the extent of IH was influenced not by stent length but by DES types, different biological effects in various types of DES may affect the severity of IH.

Limitations

First, this study is retrospective. In 88% of the cases, IVUS was performed during repeated revascularization for the

treatment of severe and symptomatic restenotic lesions. Because selection bias might affect the data, our results cannot be extended to the general population with the variable degree of ISR. Second, IVUS data immediately after stenting were not included in this analysis. However, because of the rarity of DES recoil, our interpretation of the relationship between underexpansion and ISR seems reasonable. Third, the cutoff for defining significant luminal narrowing and underexpansion is still a matter of debate, especially in small or very large-sized vessels. Fourth, although stent fracture has been known to play a role in the development of ISR, the implication of DES fracture on the ISR was not evaluated in the current study because of the low incidence of stent fracture. Finally, the current study could not demonstrate any different properties of ISR patterns among 3 DES groups because of small sample size.

Table 4. Angiographic Restenotic Patterns Among 3 DES Types

	Total	DES Type		
		SES	PES	ZES
Angiographic DS >50%, No.	82	37	30	15
Class I	57 (70%)	28 (75%)	19 (66%)	10 (67%)
Class IA	0 (0%)	0 (0%)	0 (0%)	0 (0%)
Class IB	39 (48%)	23 (62%)	11 (37%)	5 (33%)
Class IC	15 (18%)	3 (8%)	8 (27%)	4 (27%)
Class ID confined to body	1 (1%)	1 (3%)	0 (0%)	0 (0%)
Class ID involving margins	2 (2%)	1 (3%)	0 (0%)	1 (7%)
Class II	20 (24%)	5 (14%)	10 (33%)	5 (33%)
Class III	1 (1%)	1 (3%)	0 (0%)	0 (0%)
Class IV	4 (5%)	3 (8%)	1 (3%)	0 (0%)

Class I indicates focal (IA, articulation or gap; IB, margin; IC, focal body; ID, multifocal); Class II, diffuse intrastent; Class III, diffuse proliferative; and Class IV, diffuse total occlusion.

Table 5. IVUS Patterns of Restenosis Among 3 DES Types

	All	SES	PES	ZES
IVUS MLA <4.0 mm ² , No.	76	33	28	15
Focal	36 (47%)	17 (52%)	12 (43%)	7 (47%)
Focal body	27 (35%)	14 (43%)	7 (25%)	6 (40%)
Focal margin	9 (12%)	3 (9%)	5 (18%)	1 (7%)
Multifocal	9 (12%)	3 (9%)	6 (21%)	0 (0%)
Multifocal body	6 (8%)	2 (6%)	4 (14%)	0 (0%)
Multifocal margin	3 (4%)	1 (3%)	2 (7%)	0 (0%)
Diffuse	31 (41%)	13 (39%)	10 (36%)	8 (53%)
Diffuse body	12 (16%)	6 (18%)	4 (14%)	2 (13%)
Diffuse margin	19 (25%)	7 (21%)	6 (22%)	6 (40%)

Acknowledgments

We thank The Korea Health 21 R&D Project, Ministry of Health & Welfare, Republic of Korea (A090264).

Disclosures

None.

References

- Liistro F, Stankovic G, Di Mario C, Takagi T, Chieffo A, Moshiri S, Montorfano M, Carlino M, Briguori C, Pagnotta P, Albiero R, Corvaja N, Colombo A. First clinical experience with a paclitaxel derivate-eluting polymer stent system implantation for in-stent restenosis: immediate and long-term clinical and angiographic outcome. *Circulation*. 2002;105:1883–1886.
- Finn AV, Nakazawa G, Joner M, Kolodgie FD, Mont EK, Gold HK, Virmani R. Vascular responses to drug eluting stents: importance of delayed healing. *Arterioscler Thromb Vasc Biol*. 2007;27:1500–1510.
- Park DW, Hong MK, Mintz GS, Lee CW, Song JM, Han KH, Kang DH, Cheong SS, Song JK, Kim JJ, Weissman NJ, Park SW, Park SJ. Two-year follow-up of the quantitative angiographic and volumetric intravascular ultrasound analysis after nonpolymeric paclitaxel-eluting stent implantation: late “catch-up” phenomenon from ASPECT Study. *J Am Coll Cardiol*. 2006;48:2432–2439.
- Mehran R, Dangas G, Abizaid AS, Mintz GS, Lansky AJ, Satler LF, Pichard AD, Kent KM, Stone GW, Leon MB. Angiographic patterns of in-stent restenosis: classification and implications for long-term outcome. *Circulation*. 1999;100:1872–1878.
- Ryan TJ, Faxon DP, Gunnar RM, Kennedy JW, King SB III, Loop FD, Peterson KL, Reeves TJ, Williams DO, Winters WL Jr. Guidelines for percutaneous transluminal coronary angioplasty. A report of the American College of Cardiology/American Heart Association Task Force on Assessment of Diagnostic and Therapeutic Cardiovascular Procedures (Subcommittee on Percutaneous Transluminal Coronary Angioplasty). *Circulation*. 1988;78:486–502.
- Popma JJ, Leon MB, Moses JW, Holmes DR Jr, Cox N, Fitzpatrick M, Douglas J, Lambert C, Mooney M, Yakubov S, Kuntz RE; SIRIUS Investigators. Quantitative assessment of angiographic restenosis after sirolimus-eluting stent implantation in native coronary arteries. *Circulation*. 2004;110:3773–3780.
- Ellis SG, Popma JJ, Lasala JM, Koglin JJ, Cox DA, Hermiller J, O’Shaughnessy C, Mann JT, Turco M, Caputo R, Bergin P, Greenberg J, Stone GW. Relationship between angiographic late loss and target lesion revascularization after coronary stent implantation: analysis from the TAXUS-IV trial. *J Am Coll Cardiol*. 2005;45:1193–1200.
- Lee SW, Park SW, Kim YH, Yun SC, Park DW, Lee CW, Hong MK, Rhee KS, Chae JK, Ko JK, Park JH, Lee JH, Choi SW, Jeong JO, Seong IW, Cho YH, Lee NH, Kim JH, Chun KJ, Kim HS, Park SJ. A randomized comparison of sirolimus- versus paclitaxel-eluting stent implantation in patients with diabetes mellitus. *J Am Coll Cardiol*. 2008;52:727–733.
- Park SJ, Shim WH, Ho DS, Raizner AE, Park SW, Hong MK, Lee CW, Choi D, Jang Y, Lam R, Weissman NJ, Mintz GS. A paclitaxel-eluting stent for the prevention of coronary restenosis. *N Engl J Med*. 2003;348:1537–1545.
- Mintz GS, Weissman NJ, Teirstein PS, Ellis SG, Waksman R, Russo RJ, Moussa I, Tripuraneni P, Jani S, Kobayashi Y, Giorgianni JA, Pappas C, Kuntz RA, Moses J, Leon MB. Effect of intracoronary gamma-radiation therapy on in-stent restenosis: an intravascular ultrasound analysis from the gamma-1 study. *Circulation*. 2000;102:2915–2918.
- Sonoda S, Morino Y, Ako J, Terashima M, Hassan AH, Bonneau HN, Leon MB, Moses JW, Yock PG, Honda Y, Kuntz RE, Fitzgerald PJ; SIRIUS Investigators. Impact of final stent dimensions on long-term results following sirolimus-eluting stent implantation: serial intravascular ultrasound analysis from the Sirius trial. *J Am Coll Cardiol*. 2004;43:1959–1963.
- Abizaid A, Mintz GS, Pichard AD, Kent KM, Satler LF, Walsh CL, Popma JJ, Leon MB. Clinical, intravascular ultrasound, and quantitative angiographic determinants of the coronary flow reserve before and after percutaneous transluminal coronary angioplasty. *Am J Cardiol*. 1998;82:423–428.
- Nishioka T, Amanullah AM, Luo H, Berglund H, Kim CJ, Nagai T, Hakamata N, Katsushika S, Uehata A, Takase B, Isojima K, Berman DS, Siegel RJ. Clinical validation of intravascular ultrasound imaging for assessment of coronary stenosis severity: comparison with stress myocardial perfusion imaging. *J Am Coll Cardiol*. 1999;33:1870–1878.
- Rathore S, Terashima M, Katoh O, Matsuo H, Tanaka N, Kinoshita Y, Kimura M, Tuschikane E, Nasu K, Ehara M, Asakura K, Asakura Y, Suzuki N, Airoldi F, Michev I, Montorfano M, Sangiorgi GM, Bonizzoni E, Colombo A. Patterns of restenosis after drug-eluting stent implantation: insights from a contemporary and comparative analysis of sirolimus- and paclitaxel-eluting stents. *Eur Heart J*. 2006;27:2330–2337.
- Moses JW, Leon MB, Popma JJ, Fitzgerald PJ, Holmes DR, O’Shaughnessy C, Caputo RP, Kereiakes DJ, Williams DO, Teirstein PS, Jaeger JL, Kuntz RE. SIRIUS Investigators. Sirolimus-eluting stents versus standard stents in patients with stenosis in a native coronary artery. *N Engl J Med*. 2003;349:1315–1323.
- Popma JJ, Popma JJ, Leon MB, Moses JW, Holmes DR Jr, Cox N, Fitzpatrick M, Douglas J, Lambert C, Mooney M, Yakubov S, Kuntz RE. SIRIUS Investigators. Quantitative assessment of angiographic restenosis after sirolimus-eluting stent implantation in native coronary arteries. *Circulation*. 2004;110:3773–3780.
- Stone GW, Ellis SG, Cox DA, Hermiller J, O’Shaughnessy C, Mann JT, Turco M, Caputo R, Bergin P, Greenberg J, Popma JJ, Russell ME. TAXUS-IV Investigators. A polymer-based, paclitaxel-eluting stent in patients with coronary artery disease. *N Engl J Med*. 2004;350:221–231.
- Ohlmann P, Mintz GS, Kim SW, Pichard AD, Satler LF, Kent KM, Suddath WO, Waksman R, Weissman NJ. Intravascular ultrasound findings in patients with restenosis of sirolimus- and paclitaxel-eluting stents. *Int J Cardiol*. 2008;125:11–15.

CLINICAL PERSPECTIVE

We used intravascular ultrasound (IVUS) to (1) clarify the mechanisms of luminal loss after drug-eluting stent (DES) implantation and (2) classify morphologic patterns of in-stent restenosis (ISR). Overall, 76 lesions had IVUS-defined ISR; 32 (42%) had stent underexpansion (minimal stent area [MSA] <5 mm²); and 71 (93%) had IH area >50% of stent area. Total stent length negatively correlated with MSA ($r = -0.613$, $P < 0.001$) as well as with stent area at the minimum lumen site ($r = -0.436$, $P < 0.001$) but not with MLA ($r = -0.084$, $P = 0.472$). Underexpansion was present at the minimum lumen site in 15 of 43 (35%) lesions with stent length >28 mm, even though there was significant IH in 34 (79%) lesions; conversely, in 32 of 33 (97%) lesions with stent length ≤28 mm, the minimum lumen site was not associated with stent underexpansion but significant IH. IVUS-defined focal ISR was the most common (47%) pattern of ISR. Compared with focal ISR, normalized vessel, stent, lumen, and plaque volumes were smaller in diffuse and multifocal than focal ISR, with no difference in IH extent. The current study demonstrated that IH was the dominant mechanism of ISR in most DES restenosis. Nevertheless, underexpansion associated with longer stent length remained an important preventable mechanism of ISR.