

Preintervention Angiographic and Intravascular Ultrasound Predictors for Side Branch Compromise After a Single-Stent Crossover Technique

Soo-Jin Kang, MD, PhD^a, Gary S. Mintz, MD^b, Won-Jang Kim, MD^a, Jong-Young Lee, MD^a, Duk-Woo Park, MD, PhD^a, Seung-Whan Lee, MD, PhD^a, Young-Hak Kim, MD, PhD^a, Cheol Whan Lee, MD, PhD^a, Seong-Wook Park, MD, PhD^a, and Seung-Jung Park, MD, PhD^{a,*}

A single stent crossover technique is the most common approach to treating bifurcation lesions. In 90 bifurcation lesions with side branch (SB) angiographic diameter stenosis <75%, we assessed preintervention intravascular ultrasound (IVUS; of main branch [MB] and SB) predictors for SB compromise (fractional flow reserve [FFR] <0.80) after a single stent crossover. Minimal lumen area (MLA) was measured within each of 4 segments (MB just distal to the carina, polygon of confluence, MB just proximal to polygon of confluence, and SB ostium). All lesions showed Thrombolysis In Myocardial Infarction grade 3 flow in the SB after MB stenting. Although angiographic diameter stenosis at the SB ostium increased from $26 \pm 15\%$ before the procedure to $36 \pm 21\%$ after stenting ($p = 0.001$), FFR <0.80 was observed in only 16 patients (18%). Negative remodeling (remodeling index <1) was seen in 83 (92%) lesions but did not correlate with FFR after stenting. Independent predictors for FFR after stenting were maximal balloon pressure ($p = 0.002$) and MLA of SB ostium before percutaneous coronary intervention ($p < 0.001$), MLA within the MB just distal to the carina ($p = 0.025$), and plaque burden at the SB ostium before percutaneous coronary intervention ($p = 0.005$), but not angiographic poststenting diameter stenosis or minimal lumen diameter. For prediction of FFR <0.80 after percutaneous coronary intervention, the best cutoff of MLA within the SB ostium before percutaneous coronary intervention was 2.4 mm^2 (sensitivity 94%, specificity 69%). Also, the cutoff of plaque burden within the SB ostium before percutaneous coronary intervention was $\geq 51\%$ (sensitivity 75%, specificity 71%). In 67 lesions with an MLA $\geq 2.4 \text{ mm}^2$ or plaque burden <50% before percutaneous coronary intervention, 63 (94%) showed FFR ≥ 0.80 . However, FFR <0.80 was seen in only 12 (52%) of 23 lesions with an MLA < 2.4 mm^2 and plaque burden $\geq 50\%$. In conclusion, there do not appear to be reliable IVUS predictors of functional SB compromise after crossover stenting. © 2011 Elsevier Inc. All rights reserved. (Am J Cardiol 2011;107:1787–1793)

Bifurcation stenting remains technically challenging and is a major determinant of lower procedural success rates and adverse outcomes.^{1,2} Fractional flow reserve (FFR) <0.80 identifies ischemia-inducing stenoses with an accuracy of >90%.^{3–5} Recent studies have suggested that FFR-guided percutaneous coronary intervention is associated with decreased major adverse cardiac events in patients with multivessel coronary artery disease, especially by avoiding stent implantation into nonischemia-producing lesions.^{6–8} Furthermore, an FFR-guided provisional side branch (SB) intervention strategy in bifurcating lesions has been found to result in a low rate of functional restenosis and 9-month cardiac events.⁹ In light of these data, the role of intravascular ultrasound (IVUS) has become unclear. Thus,

the aims of the present study were to assess anatomic (angiographic and intravascular ultrasound) predictors before percutaneous coronary intervention of an abnormal SB FFR after percutaneous coronary intervention when a bifurcation lesion is treated using a single-stent crossover technique.

Methods

From May 2007 through February 2010, 288 patients with significant stenosis of a coronary artery bifurcation underwent drug-eluting stent implantation with single-stent crossover or provisional stent strategy. Preprocedure IVUS imaging with main branch (MB) and SB pullbacks and SB FFR measurements after MB stenting were performed in 187 lesions with an angiographic diameter stenosis of the SB ostium <75%, distal reference lumen diameter of the SB >2 mm, and lesion length of the SB ostium <10 mm by visual estimation. We then excluded patients with myocardial infarction, regional wall motion abnormality in the MB or SB territories, ejection fraction <40%, bypass graft lesions, presence of left main coronary artery disease, a sig-

^aDepartment of Cardiology, University of Ulsan College of Medicine, Asan Medical Center, Seoul, Korea; ^bCardiovascular Research Foundation, New York, New York. Manuscript received January 9, 2011; revised manuscript received and accepted February 12, 2011.

This study was supported by Grant A090264 from the Korea Health 21 R&D Project, Ministry of Health and Welfare, Seoul, Korea.

*Corresponding author: Tel: 82-2-3010-4812; fax: 82-2-475-6898.

E-mail address: sjpark@amc.seoul.kr (S.-J. Park).

nificant distal lesion within the SB, a significant lesion within the MB proximal to the stented segment, in-stent restenosis, previous percutaneous coronary intervention, thrombus-containing lesions, predilation of SB before IVUS or FFR, inability of the IVUS imaging catheter to cross lesions in the SB because of tight stenosis or tortuosity, and SB balloon inflations at any time before SB FFR measurements. Ninety bifurcation lesions in 90 patients were analyzed in the present study. We obtained written informed consent from all patients, and the ethics committee approved this study.

Qualitative and quantitative angiographic analyses were performed according to standard techniques with automated edge-detection algorithms (CASS-5, Pie-Medical, Netherlands) in the angiographic analysis center of the Cardiovascular Research Foundation, Seoul, Korea.¹⁰ The Medina classification was used to describe the location and distribution of lesions at the bifurcation.¹¹ The angle between the proximal MB and the SB (proximal carina angle) and the angle between the MB and the SB (distal carina angle) were measured before and after stenting. Measurements were performed in the angiographic view with the least foreshortening of the 3 segments.^{12,13}

IVUS imaging was performed after intracoronary administration of nitroglycerin 0.2 mg using motorized transducer pullback (0.5 mm/s) and a commercial scanner (Boston Scientific/SCIMED, Minneapolis, Minnesota) consisting of a rotating 40-MHz transducer within a 3.2Fr imaging sheath. Using computerized planimetry (EchoPlaque 3.0, Indec Systems, Mountain View, California), off-line IVUS analysis was performed in the IVUS core laboratory of Asan Medical Center (Seoul, Korea).

Four segments of the bifurcation before intervention were assessed using MB pullback and SB pullback. From the MB pullback, the following were identified: (1) MB just distal to the carina, (2) polygon of confluence (confluence zone of the MB and SB on longitudinal IVUS image reconstruction in parallel with the quantitative coronary angiogram-based definition suggested by Ramcharitar et al.¹² and modified for IVUS analysis),¹⁴ and (3) MB just proximal to the polygon of confluence. Separately using the SB pullback, the ostium of the SB just distal to the carina was defined. IVUS-measured minimal lumen area (MLA) was the smallest cross-sectional area within each segment. At the MLA site within each of these 4 segments, the lumen, stent, plaque plus media, and external elastic membrane areas were measured by 2-dimensional planimetry. Plaque burden was calculated as plaque plus media/external elastic membrane \times 100 (percentage). Remodeling index of the SB ostium before percutaneous coronary intervention was the ratio of external elastic membrane area at the MLA site within the SB ostium to external elastic membrane area of the distal reference segment.

Three segments of the bifurcation were assessed after stenting using MB IVUS pullback: distal MB, polygon of confluence, and proximal MB in parallel with preprocedure IVUS analysis. Minimal stent area within each of these segments was measured.¹⁴

After drug-eluting stent implantation of the MB was performed using the crossover technique and before any SB balloon inflations, FFR of the SB was measured. "Equal-

Table 1
Baseline clinical and procedural characteristics in 90 patients

Variable	
Age (years)	60 \pm 9
Men	66 (73%)
Smoker	23 (26%)
Hypertension	39 (43%)
Hypercholesterolemia	30 (33%)
Diabetes mellitus	15 (17%)
Left ventricular ejection fraction (%)	60 \pm 5
Previous myocardial infarction	0 (0%)
Type of side branch	
Diagonal	82 (91%)
Obtuse marginal	7 (8%)
Posterior descending	1 (1%)
Clinical presentation	
Stable angina pectoris	71 (79%)
Unstable angina pectoris	19 (21%)
Drug-eluting stent type	
Cypher	34 (38%)
Taxus	6 (7%)
Xience	13 (14%)
Endeavor Resolute	28 (31%)
Other drug-eluting stents	9 (10%)
Maximal balloon pressure in main branch (atm)	13.0 \pm 4.2
Maximal balloon size in main branch (mm)	3.5 \pm 0.3
Stent number in main branch	1.3 \pm 0.5

ization" of the 2 pressures was performed with the guide-wire sensor positioned at the guiding catheter tip. Then, the 0.014-inch pressure guidewire (St. Jude Medical, Minneapolis, Minnesota) was passed through the MB stent struts into the distal SB, and FFR was measured 5 mm distal to the SB ostium at maximal hyperemia induced by intravenous infusion of adenosine 140 μ g/kg/min through a central vein. Hyperemic pressure pullback recordings were performed as described previously.^{3,15} SB stenosis was considered functionally significant and compromised when FFR after stenting was $<$ 0.80.

All statistical analyses were performed using SPSS 10.0 (SPSS, Inc., Chicago, Illinois). All values are expressed as mean \pm 1 SD (continuous variables) or count and percentage (categorical variables). Continuous variables were compared using unpaired *t* test or nonparametric Mann-Whitney test; categorical variables were compared using chi-square statistics or Fisher's exact test. Receiver operating curve characteristics were analyzed to assess best cut-off values of IVUS parameters to determine FFR $<$ 0.80 using MedCalc (MedCalc Software, Mariakerke, Belgium). Optimal cutoff was calculated using the Youden index. Sensitivity, specificity, positive predictive value, and negative predictive value with 95% confidence intervals (CIs) were obtained. Including preprocedure and procedural variables such as maximal balloon pressure at the MB, remodeling index at the SB ostium, MLA within the distal MB, MLA within the SB ostium, plaque burden of the SB ostium, and MLA within the polygon of confluence, stepwise regression analysis was performed to determine the independent predictors of FFR after MB crossover stenting. A *p* value $<$ 0.05 was considered statistically significant.

Table 2
Angiographic data in 90 lesions pre- and post-stenting

Variable	
Pre-procedural	
Minimal lumen diameter within distal main branch (mm)	1.5 ± 0.5
Diameter stenosis of distal main branch (%)	50.9 ± 16.9
Minimal lumen diameter within proximal main branch (mm)	1.6 ± 0.5
Diameter stenosis of proximal main branch (%)	51.0 ± 15.5
Minimal lumen diameter within side branch ostium (mm)	1.8 ± 0.4
Diameter stenosis of side branch ostium (%)	26.2 ± 15.4
Minimal lumen diameter within the polygon of confluence (mm)	1.9 ± 0.5
Diameter stenosis of the polygon of confluence (%)	43.2 ± 14.6
Proximal reference lumen diameter of main branch (mm)	3.7 ± 0.5
Distal reference lumen diameter of main branch (mm)	2.6 ± 0.4
Distal reference lumen diameter of side branch (mm)	2.3 ± 0.2
Proximal carina angle (°)	156.3 ± 24.9
Distal carina angle (°)	52.2 ± 25.9
Medina classification	
1,1,1	26 (29%)
1,1,0	40 (44%)
1,0,1	7 (8%)
0,1,1	3 (3%)
1,0,0	4 (4%)
0,1,0	10 (11%)
Post-stenting at the main branch	
Minimal lumen diameter within distal main branch (mm)	2.7 ± 0.3*
Diameter stenosis of distal main branch (%)	8.3 ± 6.3*
Minimal lumen diameter within proximal main branch (mm)	3.0 ± 0.4*
Diameter stenosis of proximal main branch (%)	9.2 ± 6.7*
Minimal lumen diameter within side branch ostium (mm)	1.6 ± 0.7*
Diameter stenosis of side branch ostium (%)	36.2 ± 21.1*
Minimal lumen diameter within the polygon of confluence (mm)	3.1 ± 0.4*
Diameter stenosis of the polygon of confluence (%)	8.8 ± 6.5*
Proximal carina angle (°)	157.1 ± 13.6
Distal carina angle (°)	45.7 ± 15.2*

Median value [inter-quartile range].

* $p < 0.001$ versus before stenting.

Results

Baseline clinical and procedural characteristics are presented in Table 1. Angiographic data are presented in Table 2. In all lesions there was Thrombolysis In Myocardial Infarction grade 3 flow in the SB before and after stenting. Angiographic percent diameter stenosis at the SB ostium significantly increased from $26 \pm 15\%$ (range 2 to 70) before the procedure to $36 \pm 21\%$ (range 2 to 84) immediately after MB stenting ($p = 0.001$). The distal carina angle was decreased from $52.1 \pm 25.9^\circ$ before the procedure to $45.7 \pm 15.1^\circ$ after stenting ($p = 0.043$), whereas there was no change in proximal carina angle after MB stenting ($156.3 \pm 24.9^\circ$ vs $157.2 \pm 13.6^\circ$, $p = 0.767$).

Poststenting FFR of the SB was 0.95 ± 0.07 before adenosine and 0.88 ± 0.09 at maximal hyperemia. FFR < 0.80 at maximal hyperemia was observed in 16 patients (18%).

Table 3
Intravascular ultrasound findings before and after stenting

Intravascular ultrasound before stenting	
At distal main branch	
Minimal lumen area (mm ²)	3.0 ± 1.5
External elastic membrane area at minimal lumen area site (mm ²)	9.1 ± 3.2
Plaque burden at minimal lumen area site (%)	65.5 ± 14.3
Minimal lumen area within polygon of confluence (mm ²)	4.4 ± 2.3
At proximal main branch	
Minimal lumen area (mm ²)	4.6 ± 2.8
External elastic membrane area at minimal lumen area site (mm ²)	13.2 ± 4.0
Plaque burden at minimal lumen area site (%)	64.7 ± 17.1
At side branch ostium	
Minimal lumen area (mm ²)	2.9 ± 1.2
External elastic membrane area at minimal lumen area site (mm ²)	5.3 ± 1.8
Plaque burden at minimal lumen area site (%)	45.0 ± 15.7
At distal reference segment	
External elastic membrane area (mm ²)	6.7 ± 1.9
Mean external elastic membrane diameter (mm)	2.9 ± 0.4
Intravascular ultrasound after stenting	
Minimal stent area within distal main branch (mm ²)	6.9 ± 1.4
Minimal stent area within polygon of confluence (mm ²)	7.7 ± 1.6
Minimal stent area within distal main branch (mm ²)	8.2 ± 1.5

Neither poststenting angiographic percent diameter stenosis at the SB ostium ($r = -0.045$, $p = 0.670$) nor poststenting minimal lumen diameter at the SB ostium ($r = 0.134$, $p = 0.206$) correlated with poststenting FFR. In addition, change in distal carina angle was not related to FFR ($r = 0.102$, $p = 0.338$).

Pre- and poststenting IVUS data are listed in Table 3. Preprocedure MLA and plaque burden at the SB ostium measured 2.9 ± 1.2 mm² and $45 \pm 15\%$, respectively. IVUS-measured MLA within the SB ostium correlated with angiographic percent diameter stenosis of the SB ostium ($r = -0.382$, $p < 0.001$) before percutaneous coronary intervention.

MLA before percutaneous coronary intervention within the polygon of confluence correlated with MLA within the SB ostium ($r = 0.482$, $p < 0.001$), MLA within the MB proximal to the carina ($r = 0.237$, $p = 0.025$), and MLA within the MB distal to the carina ($r = 0.670$, $p < 0.001$). Also, the polygon of confluence was related to plaque burden at the MLA site of the SB ($r = -0.245$, $p = 0.020$) and plaque burden at the MLA site of the proximal MB ($r = -0.492$, $p < 0.001$).

Remodeling index at the SB ostium was 0.79 ± 0.12 . When negative remodeling was defined as a remodeling index < 1 , negative remodeling was observed in 83 (92%) lesions. Although the remodeling index was positively correlated with preprocedure MLA within the SB ostium ($r = 0.345$, $p = 0.001$), it was not related to preprocedure plaque burden at the SB ostium ($r = 0.092$, $p = 0.389$), and there was no direct relation between the remodeling index and poststenting SB FFR ($r = 0.200$, $p = 0.060$). There was no significant difference in remodeling index between lesions with FFR < 0.80 and those with FFR ≥ 0.80 (0.78 ± 0.15 vs 0.80 ± 0.12 , $p = 0.597$).

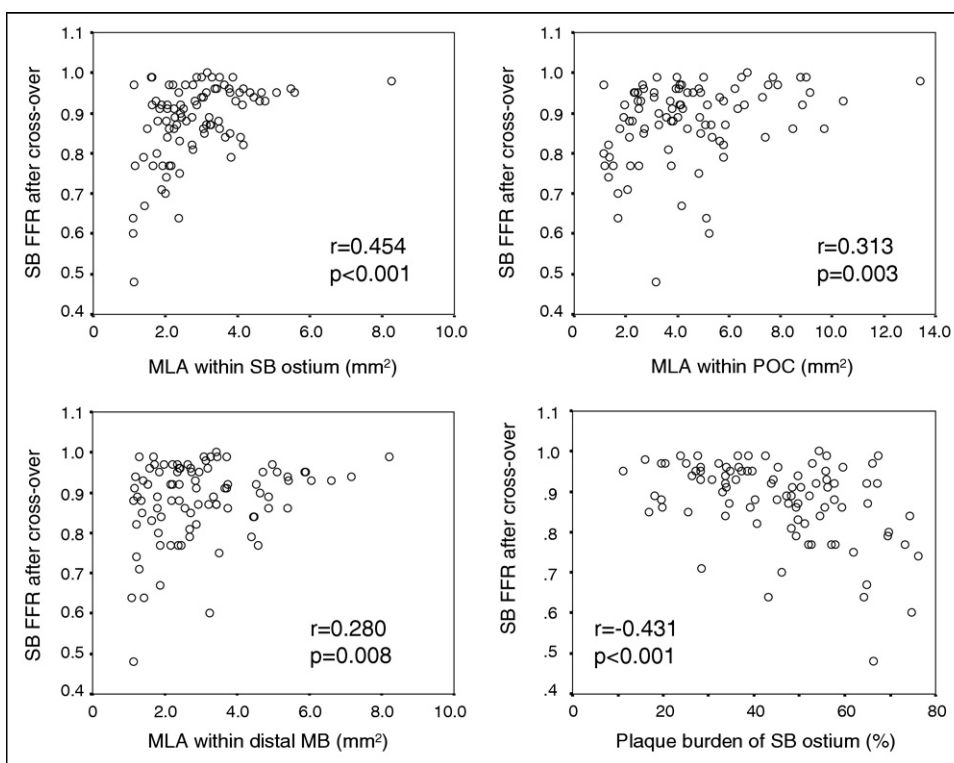


Figure 1. Correlation of preprocedure angiographic and intravascular ultrasound parameters with side branch fractional flow reserve after main branch stenting. POC = polygon of confluence.

Table 4
Correlation of preprocedure angiographic and intravascular ultrasound parameters versus fractional flow reserve of side branch after main branch stenting

Variable	r	p Value	FFR at SB After Stenting		p Value*
			<0.8	≥0.8	
Maximal balloon pressure of main branch stenting	-0.333	0.001			
Preprocedure angiography					
Minimal lumen diameter within distal main branch (mm)	0.189	0.074	1.26 (1.00-0.71)	1.45 (1.10-1.82)	0.156
Diameter stenosis of distal main branch (%)	-0.172	0.104	58.9 (45.9-63.6)	51.1 (37.0-62.5)	0.151
Minimal lumen diameter within proximal main branch (mm)	0.167	0.115	1.36 (1.04-2.09)	1.61 (1.38-2.01)	0.270
Diameter stenosis of proximal main branch (%)	-0.186	0.079	59.2 (39.3-69.9)	50.6 (39.7-60.5)	0.324
Minimal lumen diameter within polygon of confluence (mm)	0.244	0.020	1.75 (1.24-2.11)	1.89 (1.59-2.29)	0.133
Diameter stenosis of polygon of confluence (%)	-0.255	0.015	48.2 (38.5-61.2)	41.9 (30.5-50.6)	0.123
Minimal lumen diameter within side branch ostium (mm)	0.470	<0.001	1.37 (1.18-1.68)	1.93 (1.70-2.17)	0.001
Diameter stenosis of side branch ostium (%)	-0.433	<0.001	36.7 (25.1-49.6)	20.9 (14.7-30.5)	0.001
Proximal carina angle (°)	0.062	0.560	156.0 (143.6-168.7)	159.1 (147.5-168.5)	0.496
Distal carina angle (°)	-0.051	0.634	50.6 (40.4-69.3)	45.1 (31.9-64.1)	0.387
Preprocedure intravascular ultrasound					
At distal main branch					
Minimal lumen area (mm ²)	0.280	0.008	2.16 (1.28-3.24)	2.84 (1.87-3.91)	0.050
Plaque burden (%)	-0.132	0.217	69.4 (52.8-80.4)	64.4 (54.3-77.5)	0.483
Minimal lumen area within polygon of confluence (mm ²)	0.313	0.003	2.34 (1.55-4.67)	4.14 (2.73-5.96)	0.005
At proximal main branch					
Minimal lumen area (mm ²)	0.209	0.049	4.19 (2.39-5.10)	4.26 (2.35-6.66)	0.279
Plaque burden (%)	-0.071	0.508	62.5 (51.8-77.6)	66.2 (51.7-77.9)	0.808
At side branch ostium					
Minimal lumen area (mm ²)	0.454	<0.001	1.91 (1.21-2.15)	3.00 (2.23-3.76)	<0.001
Plaque burden (%)	-0.431	<0.001	60.0 (49.9-68.7)	41.6 (31.8-53.8)	<0.001

Values presented as median (interquartile range).

* Nonparametric Mann-Whitney test.

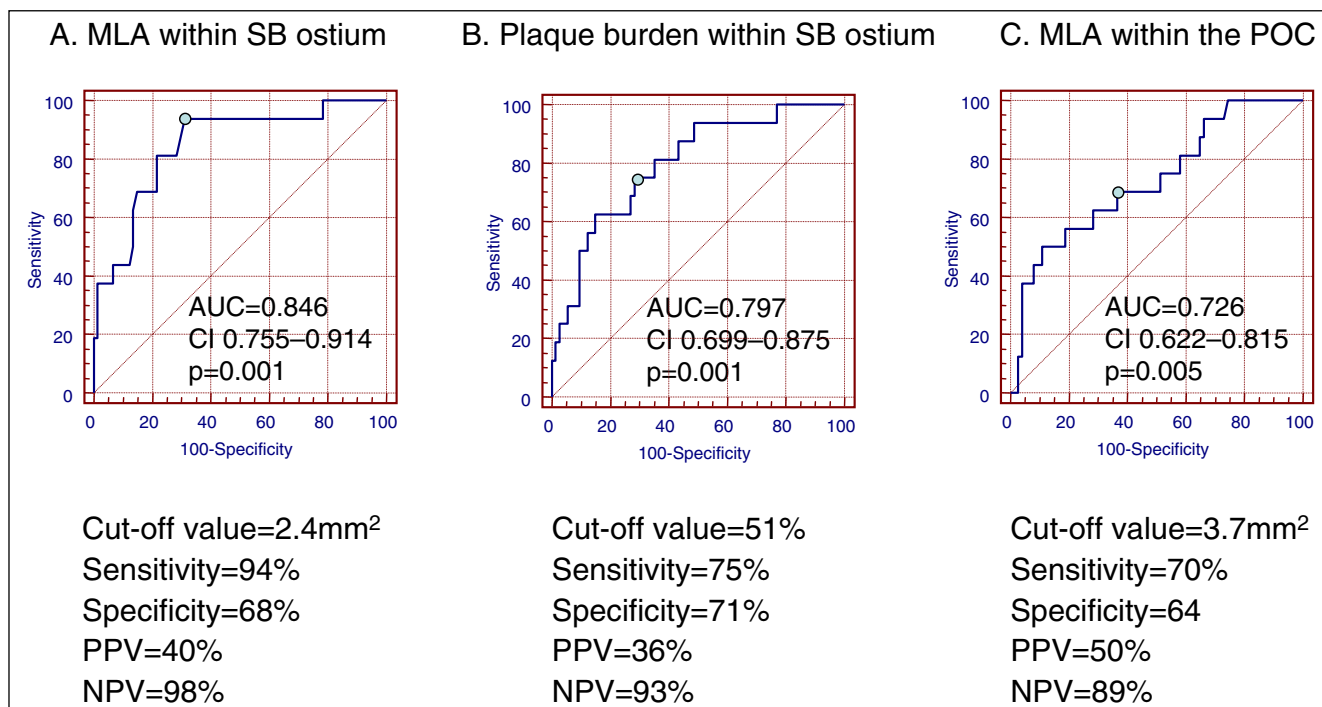


Figure 2. Cut-off values and diagnostic accuracies of intravascular ultrasound-derived predictors for side branch fractional flow reserve <0.80 after main branch stenting. (A) Preprocedure minimal lumen area within side branch ostium. (B) Preprocedure plaque burden within side branch ostium. (C) Preprocedure minimal lumen area within polygon of confluence. AUC = area under the curve; NPV = negative predictive value; PPV = positive predictive value. Other abbreviation as in Figure 1.

The correlation between FFR in the SB after percutaneous coronary intervention versus preprocedure angiographic and IVUS parameters and procedural variables are presented in Figure 1 and Table 4. Independent predictors for FFR within the SB after percutaneous coronary intervention as a continuous variable were maximal balloon pressure at the MB (beta = -0.265, 95% CI -0.010 to -0.002, p = 0.003), MLA of the SB ostium before percutaneous coronary intervention (beta = 0.216, 95% CI 0.001 to 0.035, p = 0.040), plaque burden at the SB ostium (beta = -0.296, 95% CI -0.003 to -0.001, p = 0.005), and MLA within the MB just distal to the carina before percutaneous coronary intervention (beta = 0.250, 95% CI 0.005 to 0.027, p = 0.025). When the model excluded MLA and plaque burden of the SB ostium obtained by SB pullback before percutaneous coronary intervention, independent predictors for FFR within the SB after percutaneous coronary intervention as a continuous variable were maximal balloon pressure (beta = -0.352, 95% CI -0.012 to -0.004, p <0.001), MLA within the polygon of confluence before percutaneous coronary intervention (beta = 0.267, 95% CI 0.003 to 0.019, p = 0.007), and MLA within the MB just distal to the carina before percutaneous coronary intervention (beta = 0.226, 95% CI 0.002 to 0.025, p = 0.026).

The cut-off value of MLA within the SB ostium before percutaneous coronary intervention that best predicted poststenting an SB FFR <0.80 was 2.4 mm² with a sensitivity of 94% and a specificity of 69% (area under the curve 0.846, p = 0.001; Figure 2). The cut-off value of plaque burden within the SB ostium before percutaneous coronary intervention for prediction of poststenting FFR <0.80 was

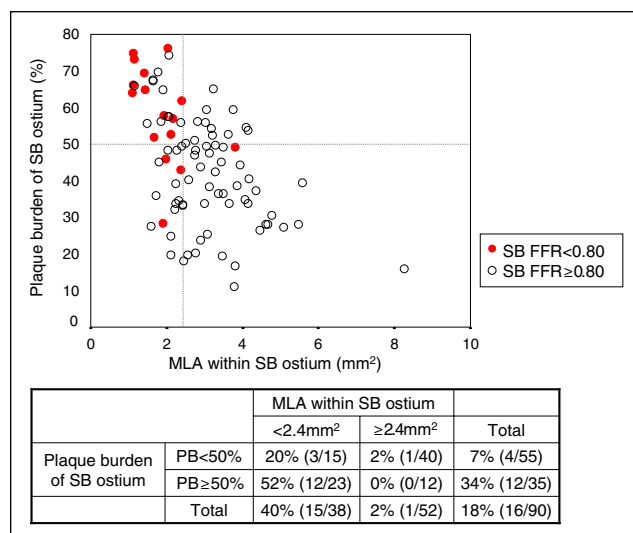


Figure 3. Prediction of poststenting fractional flow reserve of side branch using intravascular ultrasound parameters. Fractional flow reserve <0.80 (indicative of side branch compromise) (red circles) was present in 12 (52%) of 23 lesions with a preprocedure minimal lumen area <2.4 mm² and plaque burden (PB) ≥50%, in 3 (20%) of 15 lesions with minimal lumen area <2.4 mm² and plaque burden <50%, in 1 (2%) of 40 lesions with minimal lumen area ≥2.4 mm² or plaque burden <50%, and 0 of 12 lesions with minimal lumen area ≥2.4 mm² and plaque burden ≥50%. In other lesions a fractional flow reserve ≥0.80 was present (white circles).

≥51% with a sensitivity of 75% and a specificity of 71% (area under the curve 0.797, p = 0.001; Figure 2). Irrespective of plaque burden at the SB ostium, 51 of 52 (98%)

lesions with MLA within the SB ostium ≥ 2.4 mm² before percutaneous coronary intervention showed an FFR ≥ 0.80 after percutaneous coronary intervention, and there was no SB with an FFR < 0.75 . Conversely, in 38 lesions with an MLA within the SB ostium < 2.4 mm² before percutaneous coronary intervention, 15 (40%) had an FFR < 0.80 after percutaneous coronary intervention. However, when plaque burden before percutaneous coronary intervention was also considered, an FFR < 0.80 after percutaneous coronary intervention was seen in 12 (52%) of 23 lesions with MLA < 2.4 mm² and plaque burden $\geq 50\%$ before percutaneous coronary intervention, but in only 3 (20%) of 15 lesions with MLA < 2.4 mm² and plaque burden $< 50\%$. More importantly, in 67 lesions with MLA ≥ 2.4 mm² or plaque burden $< 50\%$ before percutaneous coronary intervention, 63 (94%) showed an FFR ≥ 0.80 after percutaneous coronary intervention. Thus, combining IVUS criteria of MLA and plaque burden (MLA < 2.4 mm² and plaque burden $\geq 50\%$ vs MLA ≥ 2.4 mm² or plaque burden $< 50\%$), the overall diagnostic accuracy for predicting poststenting FFR < 0.80 was 83% (Figure 3).

In 16 lesions with SB FFR < 0.80 after crossover stenting, 2 (12%) SBs were treated with T-stenting, and 10 (63%) with kissing balloon inflations without stent implantation.

Clinical follow-up was performed in all patients at 17.0 ± 7.3 months. Two patients underwent target lesion revascularization because of restenosis (1 bypass surgery and 1 percutaneous coronary intervention) and 1 patient died from cerebral infarction. There was no myocardial infarction during the follow-up period.

Discussion

The major findings of this study are summarized as follows. (1) Although angiographic percent diameter stenosis at the SB ostium significantly increased immediately after MB stenting, poststenting FFR < 0.80 within the SB occurred in only 18% of lesions with SB ostial percent diameter stenosis $< 75\%$ before the procedure. (2) In 94% of patients, an IVUS MLA within the SB ostium ≥ 2.4 mm² or plaque burden $< 50\%$ before percutaneous coronary intervention predicted an FFR ≥ 0.80 after percutaneous coronary intervention. Conversely, poststenting FFR < 0.80 could not be predicted by MLA < 2.4 mm² and plaque burden $\geq 50\%$, and an IVUS MLA < 2.4 mm² alone predicted SB compromise with high sensitivity but poor specificity. Although negative remodeling contributed to the smaller MLA within the SB ostium, it rarely affected poststenting FFR without a significant plaque burden.

Incidences of negative remodeling of the SB ostium in the present data were similar to previous data reporting that the SB ostium is most common site of MLA within the SB and 89% (24 of 27 bifurcation lesions) showed a vessel remodeling ratio < 1 at the SB ostium.¹⁶

Angiography is unreliable in the assessment of contained SB lesions and generally overestimates functional severity; this may be explained by lesion eccentricity, stent strut artifacts, and the small myocardial territory supplied by the SB.^{9,16,17} This is supported by the presented data because there was no correlation between FFR and angiographic diameter stenosis after stenting.

A previous angiographic study reported that preprocedure percent diameter stenosis of the SB and minimal lumen diameter of the MB distal to the carina independently predicted FFR of SB after MB stenting.¹⁶ In parallel with previous angiographic data, we suggested that IVUS parameters before percutaneous coronary intervention to predict FFR within the SB after percutaneous coronary intervention including MLA of the SB ostium, plaque burden of the SB ostium, and MLA within the MB just distal to the carina.

Although IVUS imaging of MB and SB pullbacks before percutaneous coronary intervention is required to identify predictors for SB compromise, SB-pullback images were available in only 1/2 the population. Furthermore, Oviedo et al¹⁸ showed that imaging the SB obliquely from the main vessel is unreliable in assessing lumen dimensions or plaque burden. Unfortunately, although routine direct imaging of the SB may be realistic in clinical practice, pre- and poststenting evaluations of the SB ostium by direct SB pullback has been limited because of technical difficulty in passing the guidewire or IVUS catheter into the SB through tight lesions (before percutaneous coronary intervention) or stent struts (after percutaneous coronary intervention), especially when the turn into the left circumflex coronary artery is tight.

We previously reported the impact of intervention before percutaneous coronary of the MLA within the polygon of confluence, a confluent zone of the MB and SB just proximal to the carina, on long-term clinical outcomes after percutaneous coronary intervention for left main coronary artery bifurcation.¹⁴ In the present analysis preprocedure MLA within the polygon of confluence correlated with stenosis severity of the proximal and distal MB and SB ostia, respectively. Excluding IVUS variables obtained from SB pullback, preprocedure MLA within the polygon of confluence < 3.7 mm² predicted an FFR < 0.80 after stenting with a sensitivity 75% and a specificity 71%. As a surrogate for the overall complexity of bifurcation disease, preprocedure MLA within the polygon of confluence using simple MB pullback may be useful for predicting FFR of the SB ostium after percutaneous coronary intervention, especially when SB pullback imaging is not available.

The present study excluded bifurcation lesions with severe stenosis of SB ostium because (1) there was technical difficulty in passing the IVUS catheter into the SB through a tight stenotic lesion or the pressure wire through stent struts after percutaneous coronary intervention and (2) most of these SBs were treated. Although we did not include follow-up angiographic and physiological assessments, Koo et al⁹ previously reported that FFR-guided provisional SB intervention strategy resulted in a low rate of functional restenosis and 9-month cardiac events. This observation was supported by the clinical follow-up data in our study. We did not compare pre- to poststenting IVUS findings within the SB because of lack of poststenting SB pullback images in this patient cohort. When using a 1-stent crossover technique, there are 2 suggested mechanisms of acute luminal loss at the SB ostium—carina shift and plaque shift.^{16,19–21} Although the higher balloon pressure of MB stenting may have an unfavorable effect on the SB compromise, the present study could not provide the precise mechanisms.

An SB FFR ≥ 0.80 after percutaneous coronary intervention was seen in 94% of lesions with an MLA $\geq 2.4 \text{ mm}^2$ or plaque burden $< 50\%$ before percutaneous coronary intervention. However, an FFR < 0.80 was seen in only 52% of 23 lesions with an MLA $< 2.4 \text{ mm}^2$ and plaque burden $\geq 50\%$. Therefore, there do not appear to be reliable IVUS predictors of functional SB compromise after crossover stenting.

- Valgimigli M, Malagutti P, Rodriguez-Granillo GA, Garcia-Garcia HM, Polad J, Tsuchida K, Regar E, Van der Giessen WJ, de Jaegere P, De Feyter P, Serruys PW. Distal left main coronary disease is a major predictor of outcome in patients undergoing percutaneous intervention in the drug-eluting stent era: an integrated clinical and angiographic analysis based on the Rapamycin-Eluting Stent Evaluated At Rotterdam Cardiology Hospital (RESEARCH) and Taxus-Stent Evaluated At Rotterdam Cardiology Hospital (T-SEARCH) registries. *J Am Coll Cardiol* 2006;47:1530–1537.
- Kim YH, Dargas GD, Solinas E, Aoki J, Parise H, Kimura M, Franklin-Bond T, Dasgupta NK, Kirtane AJ, Moussa I, Lansky AJ, Collins M, Stone GW, Leon MB, Moses JW, Mehran R. Effectiveness of drug-eluting stent implantation for patients with unprotected left main coronary artery stenosis. *Am J Cardiol* 2008;101:801–806.
- Pijls NH, De Bruyne B, Peels K, Van Der Voort PH, Bonnier HJ, Bartunek J, Koolen JJ, Koolen JJ. Measurement of fractional flow reserve to assess the functional severity of coronary artery stenoses. *N Engl J Med* 1996;334:1703–1708.
- De Bruyne B, Pijls NH, Bartunek J, Kulecki K, Bech JW, De Winter H, Van Crombrugge P, Heyndrickx GR, Wijns W. Fractional flow reserve in patients with prior myocardial infarction. *Circulation* 2001;104:157–162.
- Pijls NH, Van Gelder B, Van der Voort P, Peels K, Bracke FA, Bonnier HJ, el Gamal MI. Fractional flow reserve. A useful index to evaluate the influence of an epicardial coronary stenosis on myocardial blood flow. *Circulation* 1995;92:3183–3193.
- Berger A, Botman KJ, MacCarthy PA, Wijns W, Bartunek J, Heyndrickx GR, Pijls NH, De Bruyne B. Long-term clinical outcome after fractional flow reserve-guided percutaneous coronary intervention in patients with multivessel disease. *J Am Coll Cardiol* 2005;46:438–442.
- Wongpraparut N, Yalamanchili V, Pasnoori V, Satran A, Chandra M, Masden R, Leesar MA. Thirty-month outcome after fractional flow reserve-guided versus conventional multivessel percutaneous coronary intervention. *Am J Cardiol* 2005;96:877–884.
- Tonino PA, De Bruyne B, Pijls NH, Siebert U, Ikeno F, van't Veer M, Klauss V, Manoharan G, Engström T, Oldroyd KG, Ver Lee PN, MacCarthy PA, Fearon WF; FAME Study Investigators. Fractional flow reserve versus angiography for guiding percutaneous coronary intervention (FAME). *N Engl J Med* 2009;360:213–224.
- Koo BK, Park KW, Kang HJ, Cho YS, Chung WY, Youn TJ, Chae IH, Choi DJ, Tahk SJ, Oh BH, Park YB, Kim HS. Physiological evaluation of the provisional side-branch intervention strategy for bifurcation lesions using fractional flow reserve. *Eur Heart J* 2008;29:726–732.
- Ryan TJ, Faxon DP, Gunnar RM, Kennedy JW, King SB III, Loop FD, Peterson KL, Reeves TJ, Williams DO, Winters WL Jr. Guidelines for percutaneous transluminal coronary angioplasty. A report of the American College of Cardiology/American Heart Association Task Force on Assessment of Diagnostic and Therapeutic Cardiovascular Procedures (Subcommittee on Percutaneous Transluminal Coronary Angioplasty). *Circulation* 1988;78:486–502.
- Medina A, Suárez de Lezo J, Pan M. [A new classification of coronary bifurcation lesions]. *Rev Esp Cardiol* 2006;59:183.
- Ramcharitar S, Onuma Y, Aben JP, Consten C, Weijers B, Morel MA, Serruys PW. A novel dedicated quantitative coronary analysis methodology for bifurcation lesions. *Eurointervention* 2008;3:553–557.
- Girasis C, Serruys PW, Onuma Y, Colombo A, Holmes DR Jr, Feldman TE, Bass EJ, Leadley K, Dawkins KD, Morice MC. 3-Dimensional bifurcation angle analysis in patients with left main disease: A substudy of the SYNTAX trial (SYnergy Between Percutaneous Coronary Intervention with TAXus and Cardiac Surgery). *JACC Cardiovasc Interv* 2010;3:41–48.
- Kang SJ, Mintz GS, Kim WJ, Lee JY, Park DW, Yun SC, Lee SW, Kim YH, Lee CW, Han KH, Kim JJ, Park SW, Park SJ. Effect of intravascular ultrasound findings on long-term repeat revascularization in patients undergoing drug-eluting stent implantation for severe unprotected left main bifurcation narrowing. *Am J Cardiol* 2011;107:367–373.
- Pijls NH, van Schaardenburgh P, Manoharan G, Boersma E, Bech JW, van't Veer M, Bär F, Hoorntje J, Koolen J, Wijns W, de Bruyne B. Percutaneous coronary intervention of functionally nonsignificant stenosis: 5-year follow-up of the DEFER Study. *J Am Coll Cardiol* 2007;49:2105–2111.
- Koo BK, Waseda K, Kang HJ, Kim HS, Nam CW, Hur SH, Kim JS, Choi D, Jang Y, Hahn JY, Gwon HC, Yoon MH, Tahk SJ, Chung WY, Cho YS, Choi DJ, Hasegawa T, Kataoka T, Oh SJ, Honda Y, Fitzgerald PJ, Fearon WF. Anatomic and functional evaluation of bifurcation lesions undergoing percutaneous coronary intervention. *Circ Cardiovasc Interv* 2010;3:113–119.
- Koo BK, Kang HJ, Youn TJ, Chae IH, Choi DJ, Kim HS, Sohn DW, Oh BH, Lee MM, Park YB, Choi YS, Tahk SJ. Physiologic assessment of jailed side branch lesions using fractional flow reserve. *J Am Coll Cardiol* 2005;46:633–637.
- Oviedo C, Maehara A, Mintz GS, Tsujita K, Kubo T, Doi H, Castellanos C, Lansky AJ, Mehran R, Dargas G, Leon MB, Stone GW, Templin B, Araki H, Ochiai M, Moses JW. Is accurate intravascular ultrasound evaluation of the left circumflex ostium from a left anterior descending to left main pullback possible? *Am J Cardiol* 2010;105:948–954.
- Gil RJ, Vassilev D, Formuszewicz R, Rusicka-Piekarz T, Doganov A. The carina angle-new geometrical parameter associated with periprocedural side branch compromise and the long-term results in coronary bifurcation lesions with main vessel stenting only. *J Interv Cardiol* 2009;22(suppl):E1–E10.
- Shimada Y, Courtney BK, Nakamura M, Hongo Y, Sonoda S, Hassan AH, Yock PG, Honda Y, Fitzgerald PJ. Intravascular ultrasonic analysis of atherosclerotic vessel remodeling and plaque distribution of stenotic left anterior descending coronary arterial bifurcation lesions upstream and downstream of the side branch. *Am J Cardiol* 2006;98:193–196.
- Vassilev D, Gil R. Clinical verification of a theory for predicting side branch stenosis after main vessel stenting in coronary bifurcation lesions. *J Interv Cardiol* 2008;21:493–503.